



The SCIENCE BEHIND

VELSCOPE[®] Vx

Enhanced Oral Assessment

Clinical Studies

Table Of Contents

Effective Lesion Detection

Direct Fluorescence Visualization of Clinically Occult High-Risk Oral Premalignant Disease Using a Simple Hand-Held Device 3

Clinically non-apparent lesions

Sensitivity of Direct Tissue Fluorescence Visualization in Screening for Oral Premalignant Lesions in General Practice 4

VELscope in a general practice: A retrospective analysis

Narrow Band (Light) Imaging of Oral Mucosa in Routine Dental Patients. Part I: Assessment of Value in Detection of Mucosal Changes 5

Large prospective study in a non-high risk population

Clinical Evaluation of an Autofluorescence Diagnostic Device for Oral Cancer Detection: A Prospective Randomized Diagnostic Study 6

Prospective randomized comparative study in patients with high-risk lesions

Surgical Margin Identification

Fluorescence Visualization Detection of Field Alterations in Tumor Margins of Oral Cancer Patients 7

VELscope and assessment of lesion margins

Reduction in Reoccurrence

Tracing the "At-Risk" Oral Mucosa Field with Autofluorescence: Steps Toward Clinical Impact 8

Recurrence rates after VELscope-assisted lesion removal

References 9

Direct Fluorescence Visualization of Clinically Occult High-Risk Oral Premalignant Disease Using a Simple Hand-Held Device

Poh et al. *Head & Neck*, January 2007.

Background

A considerable proportion of oral cancer and precancer is not clinically apparent and could contribute significantly to the late diagnosis and high mortality of oral cancer. A simple method to identify such occult change is needed.

Methods

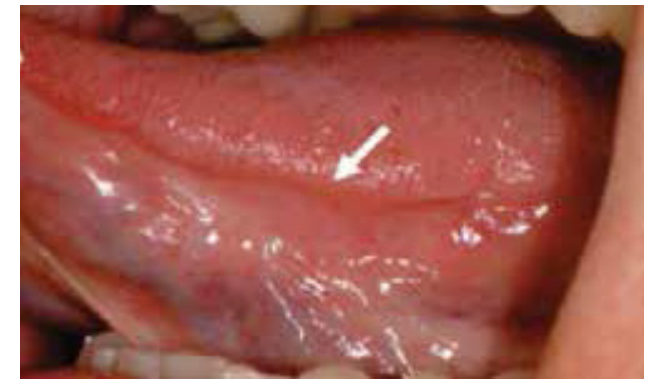Patients in the Oral Dysplasia Clinics at British Columbia are currently being examined with a simple hand-held device that permits the direct visualization of alterations to auto-fluorescence in the oral cavity. Tissue showing loss of auto-fluorescence is biopsied.

Results

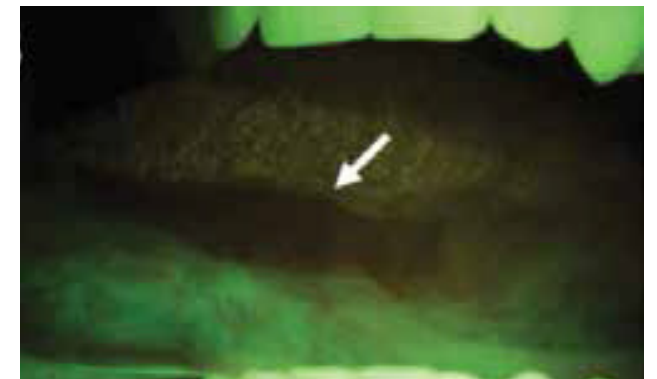
Three representative cases are presented involving occult lesions that were identified with fluorescence visualization during longitudinal follow-up, resulting in the diagnosis of a primary dysplasia in Case 1, a second primary cancer in Case 2, and cancer recurrence in Case 3.

Conclusions

This is the first report of the diagnosis of occult oral disease using a simple noninvasive device. These early examples indicate the potential value of this technology to guide the management of patients with oral lesions, facilitating the detection of high-risk changes not apparent with white-light visualization.



Occult lesion at the left ventral tongue under white light



Fluorescence visualization of the same lesion demonstrating that a loss of fluorescence can accompany minimal, or no changes, as observed under normal lighting

Sensitivity of Direct Tissue Fluorescence Visualization in Screening for Oral Premalignant Lesions in General Practice

Huff et al, *General Dentistry*, Jan/Feb 2009.

Background

Various specialty clinics and research centers have conducted studies of direct tissue fluorescence visualization as a screening technique for oral premalignant lesions and early oral squamous cell carcinoma (OSCC). The effectiveness of the VELscope in a private practice setting is unknown. This pilot study is the first report to assess the VELscope system as a screening adjunct among lower-risk populations seen by a primary care clinician in a general practice setting.

Methods

This study involved a retrospective comparison of two oral cancer screening examination protocols conducted on a presumably low-risk patient population seen in a private general dentistry practice. For one year, all patients age 12 or older received oral examinations, according to a standard oral cancer screening protocol. The following year, the same population was examined according to the same protocol with the addition of direct tissue fluorescence visualization using the VELscope.

Results

Screening with incandescent light examination yielded a prevalence of mucosal abnormalities of 0.83%, none of which were premalignant. Screening with incandescent light examination combined with direct tissue fluorescence visualization yielded a 1.3% prevalence of mucosal abnormalities; based on surgical biopsy and histopathologic examination, 83% of these were potentially premalignant epithelial dysplasia.

Conclusions

In the present study, routine incorporation of the VELscope in the examination protocol for low-risk adolescents and adults in a general dental practice proved useful in identifying occult, potentially premalignant lesions that were not identified when the VELscope was not used.

Years of Study	Oral Screening Protocol	Number of Patients	Number of Brushed Specimens	Brush Analysis Results		Surgical Biopsy Results	
				No Abnormality	Abnormal	Benign	Premalignant
12/1/05 to 12/1/06	White Light Exam	959	86	of 8	2 of 8	2 of 2	0 of 2
12/1/06 to 12/1/07	White Light & Fluorescent Exam	905	12	0 of 12	12 of 12	2 of 12	10 of 12

In the year after the VELscope was added to the examination protocol, 10 premalignant lesions were discovered compared to none the year before.

Narrow Band (Light) Imaging of Oral Mucosa in Routine Dental Patients. Part I: Assessment of Value in Detection of Mucosal Changes

Truelove, *General Dentistry*, 2011.

Purpose

The purpose of this investigation was to determine the value of adding narrow band (light) imaging (NBI) to the standard oral soft tissue examination process used to detect mucosal change. [Note: NBI is also referred to as tissue fluorescence visualization and is provided through the use of VELscope technology.]

Methods

A total of 620 dental patients who came to the clinic for regular dental evaluation or for treatment of acute dental problems were given a standard oral soft tissue examination by dental students under faculty supervision. The results of this white light examination were recorded after the tissues were examined with NBI, at which point areas with a loss of fluorescence (LOF) were recorded. The nature of the tissue change was classified clinically as normal variation, inflammatory, traumatic, dysplastic, or other, and patients were categorized depending on their clinical findings: normal, need follow-up visit, or immediate biopsy. Risk factors related to oral dysplasia also were recorded. The addition of NBI added between one and two minutes to the examination process.

Results

Of the 620 examinations, an area with a LOF suggestive of pathology was detected in 69 subjects (11.1%). After a second immediate evaluation, 28 of the 69 subjects were scheduled for follow-up or biopsy. None of the lesions discovered in these 28 subjects had been detected using standard (white light) examination. Thus, adding NBI to the routine clinical examination resulted in detection of changes not seen with white light examination in 11.1% of patients; of these, a small but important number were found to have otherwise undetected persistent changes representing inflammatory lesions or potentially dangerous oral dysplasia.

Conclusions

Adding Narrow band (light) imaging of oral mucosa as an adjunctive diagnostic procedure improved the quality and outcome of the examination process.

Lesions Undetected by Routine Clinical Examination

Lesion Biopsy Diagnosis	No. of Patients
Lichen Planus	2
Inflammation	2
Mild dysplasia	3
Mild to moderate dysplasia	2

9 of the 28 patients scheduled for follow-up had lesions with concerning biopsy results

Clinical Evaluation of an Autofluorescence Diagnostic Device for Oral Cancer Detection: A Prospective Randomized Diagnostic Study

Rana et al, Eur J Cancer Prev. 2012 Jan 2.

Background

The prognosis for patients with oral squamous cell carcinoma remains poor despite advances in multi-modal treatment concepts. Early diagnosis and treatment is the key to improved patient survival. A device (VELscope) that uses autofluorescence technology, allowing direct fluorescence visualization of the oral cavity, might be a useful tool for oral cancer detection or as an adjunct to standard clinical examination.

Methods

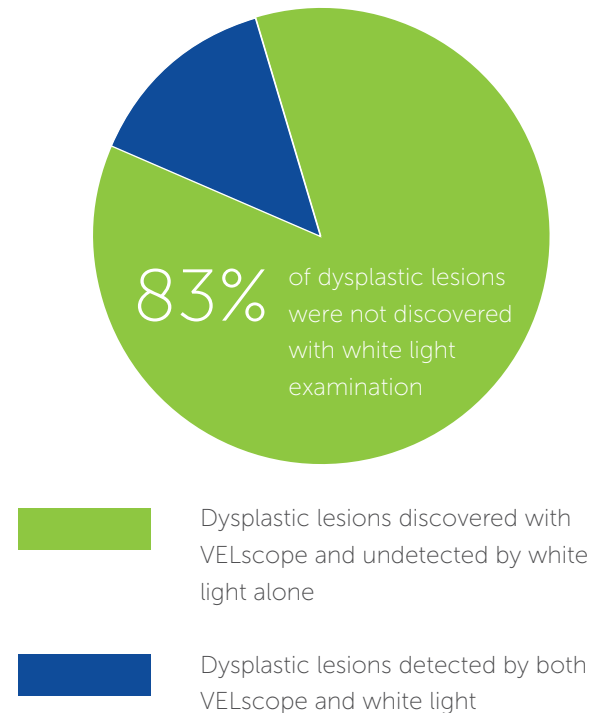
289 patients with oral premalignant lesions were randomly divided into two groups for clinical examination of precancerous oral lesions. In Group 1, 166 patients were examined conventionally with white light, and in Group 2, 123 patients were examined with the autofluorescence device (VELscope) in addition to the white light examination. Biopsies were obtained from all suspicious areas identified in both examination groups (n = 52). In the first step, baseline characteristics of the two groups (only white light vs. white light and VELscope) were compared to exclude selection bias. In the second step, for the group examined with white light and VELscope (123 patients), the diagnostic strategies were compared with regard to sensitivity and specificity using biopsy as the gold standard.

Results

The results showed that using the VELscope leads to higher sensitivity (100% instead of 17%), but to lower specificity (74% instead of 97%). Thus, we can conclude that the VELscope is a useful new diagnostic device for detection of oral cancer diseases.

Conclusion

Early diagnosis of oral cancer is a major requirement for multidisciplinary oncologic physicians. Detection should lead to less damage from cancer therapy and to better prognosis. The VELscope device, which uses visible light of 430 nm wavelength to cause fluorescent excitation of certain compounds in the tissues, will play a major part in prevention of oral cancer diseases.



Fluorescence Visualization Detection of Field Alterations in Tumor Margins of Oral Cancer Patients

Poh et al, Clin Cancer Res, November 2006.

Purpose

Genetically altered cells could become widespread across the epithelium of patients with oral cancer, often in clinically and histologically normal tissue, and contribute to recurrent disease. Molecular approaches have begun to yield information on cancer/risk fields; tissue optics could further extend our understanding of alteration to phenotype as a result of molecular change.

Methods

A simple hand-held device (VELscope) was used in the operating room to directly visualize subclinical field changes around oral cancers, documenting alteration to fluorescence. A total of 122 oral mucosa biopsies were obtained from 20 surgical specimens with each biopsy being assessed for location, fluorescence visualization (FV) status, histology, and loss of heterozygosity (LOH).

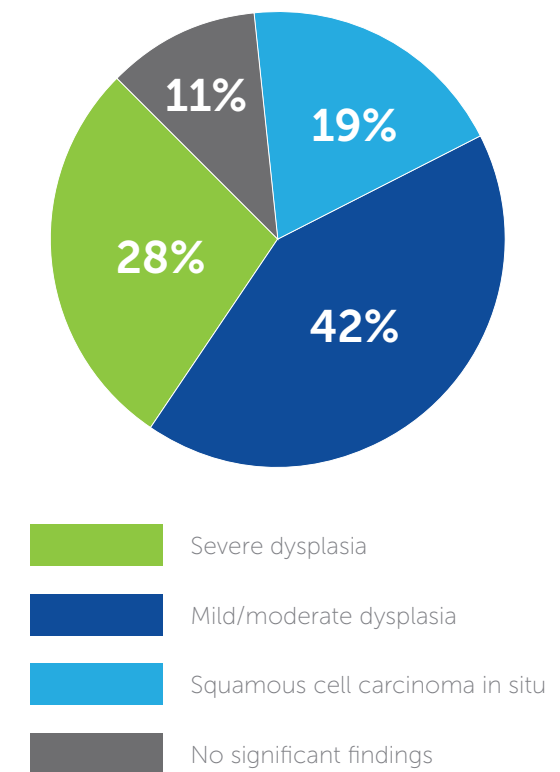
Results

All tumors showed fluorescence visualization loss (FVL). For 19 of the 20 tumors, the loss extended in at least one direction beyond the clinically visible tumor, with the extension varying from 4 to 25 mm. 32 of 36 FVL biopsies showed histologic change (including 7 squamous cell carcinoma/carcinomas in situ, 10 severe dysplasias, and 15 mild/moderate dysplasia) compared with one of the 66 FV retained (FVR) biopsies. Molecular analysis on margins with low-grade or no dysplasia showed a significant association of LOH in FVL biopsies, with LOH at 3p and/or 9p (previously associated with local tumor recurrence) present in 12 of 19 FVL biopsies compared with three of 13 FVR biopsies (P = 0.04).

Conclusions

This data has, for the first time, shown that direct FV can identify subclinical high-risk fields with cancerous and precancerous changes in the operating room setting.

Histological Change Found in FVL Biopsies Outside Visible Boundaries of Lesion



of the 20 tumors showed a loss of fluorescence beyond the clinically visible tumor

Tracing the “At-Risk” Oral Mucosa Field with Autofluorescence: Steps Toward Clinical Impact

Poh et al, *Cancer Prev Res*, May 2009.

Background

Will the use of fluorescence visualization (FV) to guide oral cancer surgery reduce tumor recurrence? The literature documents a high frequency of recurrence at the primary site (10-30% of cases) of oral cancer. [Note: The FV device utilized was the VELscope.]

Methods

A longitudinal retrospective study was conducted to explore the effect of FV in defining the surgical margin on the outcome of oral cancer surgery. Between 2004 and 2008, 60 patients with a 4 cm oral cancer entered the study. Each case was treated with surgical excision alone and was followed for at least 12 months. 38 patients had FV-guided surgery, with the surgical margin placed at 10 mm beyond the perimeter of autofluorescence loss. The remaining patients (control group) had the surgical margin placed at 10 mm beyond the tumor edge defined by standard white-light examination. Use of the FV-guided approach depended on the availability of the pathologist to attend the surgical procedure.

Results

The FV-guided and control groups had similar distributions with respect to gender, smoking habits, anatomic lesion site, and follow-up time. To date, 7 of the 60 cases (12%) have developed a recurrence of severe dysplasia or worse neoplasia at the treated site, all in the control group (25% versus 0%, P = 0.002).

Conclusion

This data suggests the utility of autofluorescence changes within this clinical setting and provides pilot support for planning a larger clinical trial aimed at establishing whether FV-guided surgery has value.

Recurrence of Severe Dysplasia or Worse at Treated Site

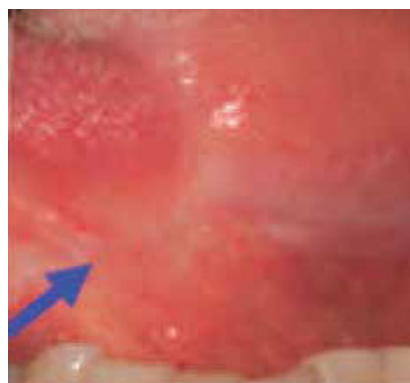FV Group	Control Group
0%	25%

References

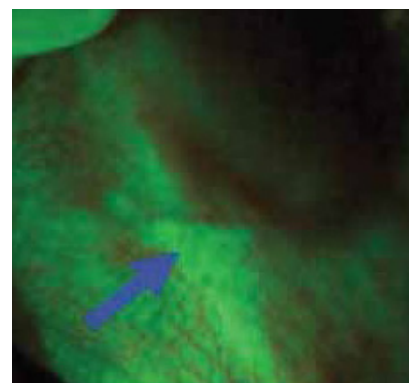
1. "Direct Fluorescence Visualization of Clinically Occult High-Risk Oral Premalignant Disease Using a Simple Hand-Held Device", Poh et al. *Head & Neck*, January 2007.
2. "Sensitivity of direct tissue fluorescence visualization in screening for oral premalignant lesions in general practice", Huff et al, *General Dentistry*, Jan/Feb 2009.
3. "Narrow Band (Light) Imaging of Oral Mucosa in Routine Dental Patients. Part I: Assessment of Value in Detection of Mucosal Changes", Truelove, *General Dentistry*, 2011.
4. "Clinical Evaluation of an Autofluorescence Diagnostic Device for Oral Cancer Detection: A Prospective Randomized Diagnostic Study", Rana et al, *Eur J Cancer Prev*. 2012 Jan 2.
5. "Fluorescence Visualization Detection of Field Alterations in Tumor Margins of Oral Cancer Patients", Poh et al, *Clin Cancer Res*, November 2006.
6. "Tracing the “At-Risk” Oral Mucosa Field with Autofluorescence: Steps Toward Clinical Impact", Poh et al, *Cancer Prev Res*, May 2009.

To view the research please visit www.denmat.com/VelscopeVx

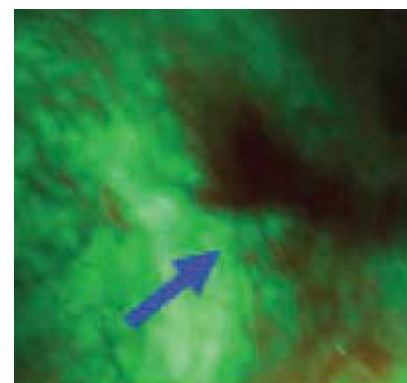
Former Smoker Examined After a Surgical Excision of Severe Epithelial Dysplasia on the Left Lateral Tongue



6 Months
White-light image of a well-healed scar on the left lateral tongue (arrow)



6 Months
The anterior aspect of this scar (arrow) under fluorescent visualization showing a dark brown region of autofluorescence loss



12 Months
The same area (arrow) showed a persistent autofluorescence loss of increased size; at 20 months after initial treatment (data not shown), a biopsy from the region of loss (arrow) showed carcinoma in situ.



Enhanced Oral Assessment

For more information

888.541.4614

www.velscope.com